

# Live cases from Golden Jubilee National Hospital

Dr M Mitchell Lindsay

Golden Jubilee National Hospital

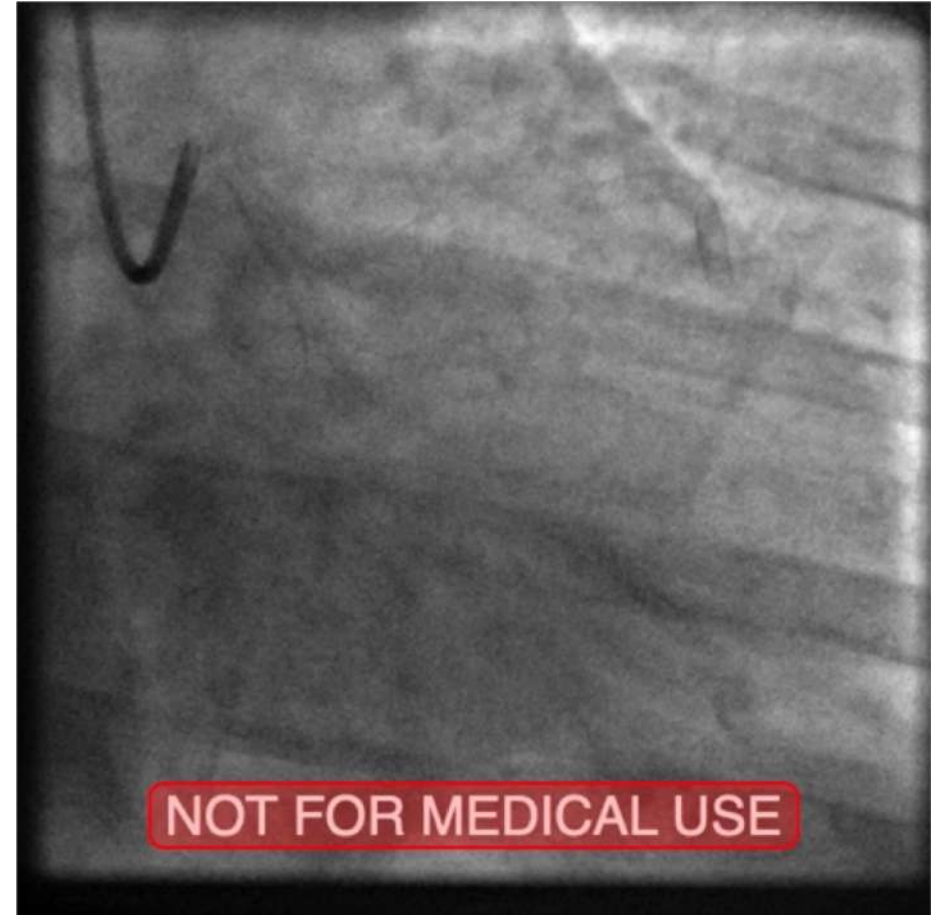
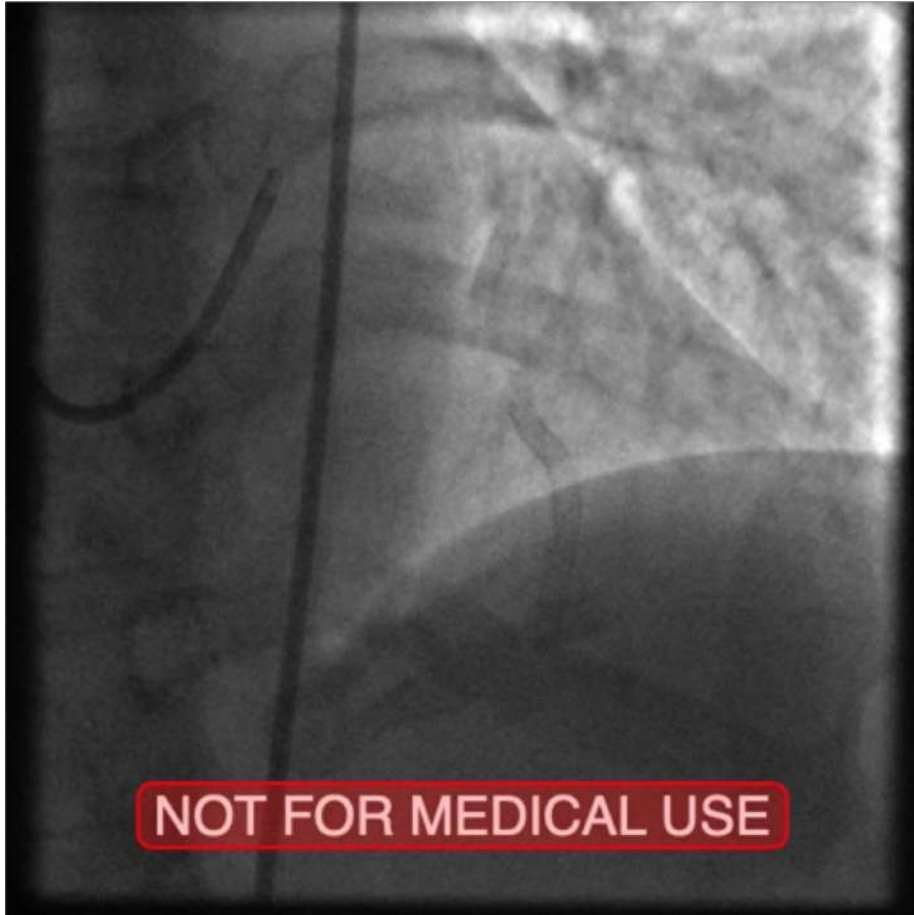
Glasgow

NO CONFLICT OF INTEREST  
TO DECLARE

# Case 1

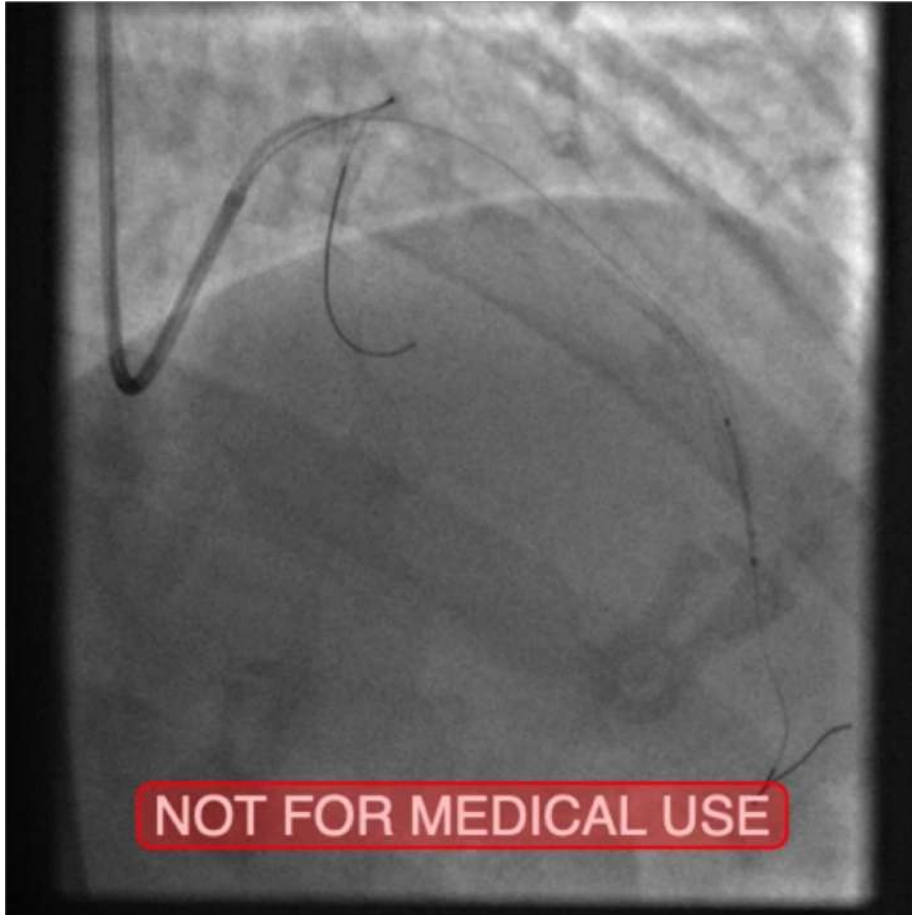
- 65 year old lady with recent NSTEMI.
- Multiple PCI previously.
- T2DM on insulin. HTN.
- PCI to LAD in 2015 ( Promus 2.75/38) with instent restenosis tx in 2017 ( Score flex and Restore DEB 3mm )
- PCI to RCA 2017.

# Diagnostic Angiography

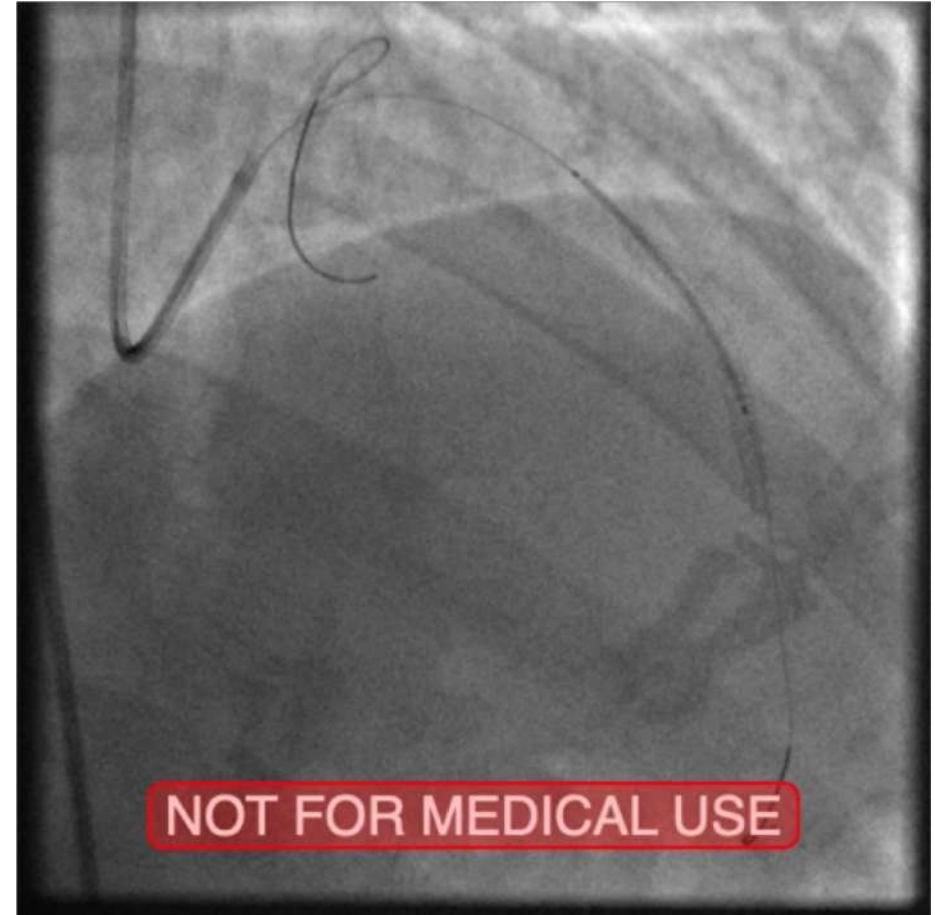


# OCT Guided PCI

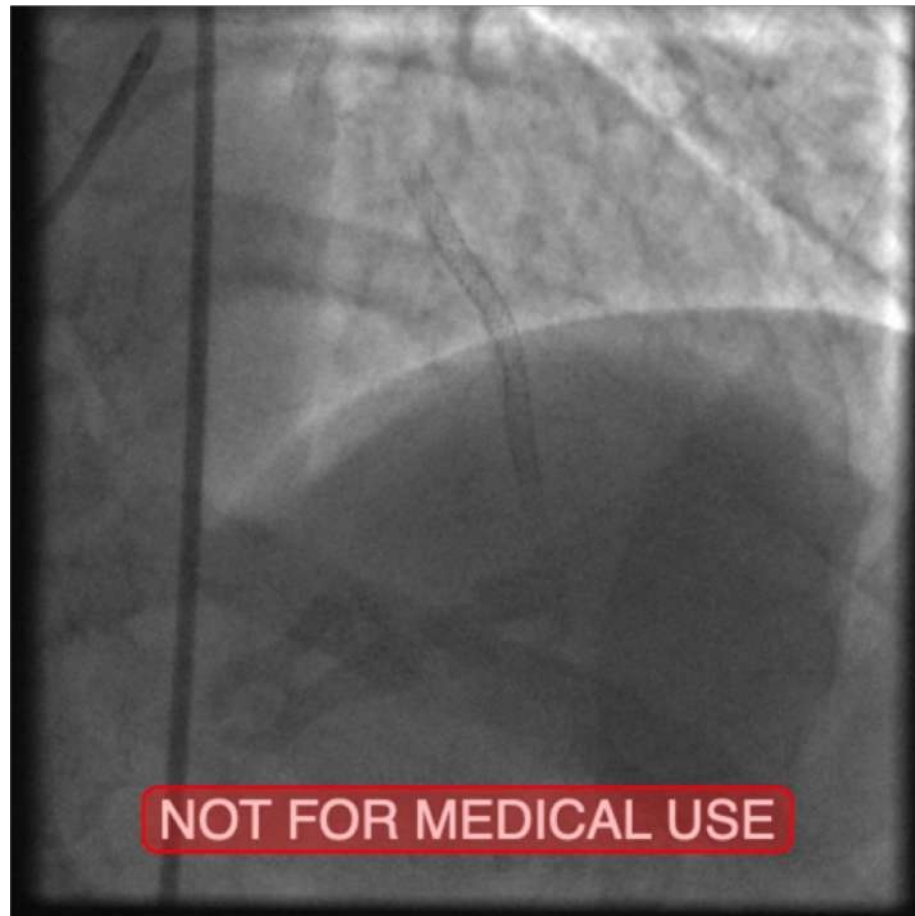
Resolute 2.5/15



Resolute 3.0/34



Final result



# Case 1 - Follow up

- 11 months post procedure
- Symptom free.
- Completed Cardiac rehab.

# Case 2

- 67yr old man
- CABG 20yrs ago
- Representing with stable angina

## Coronary angiography

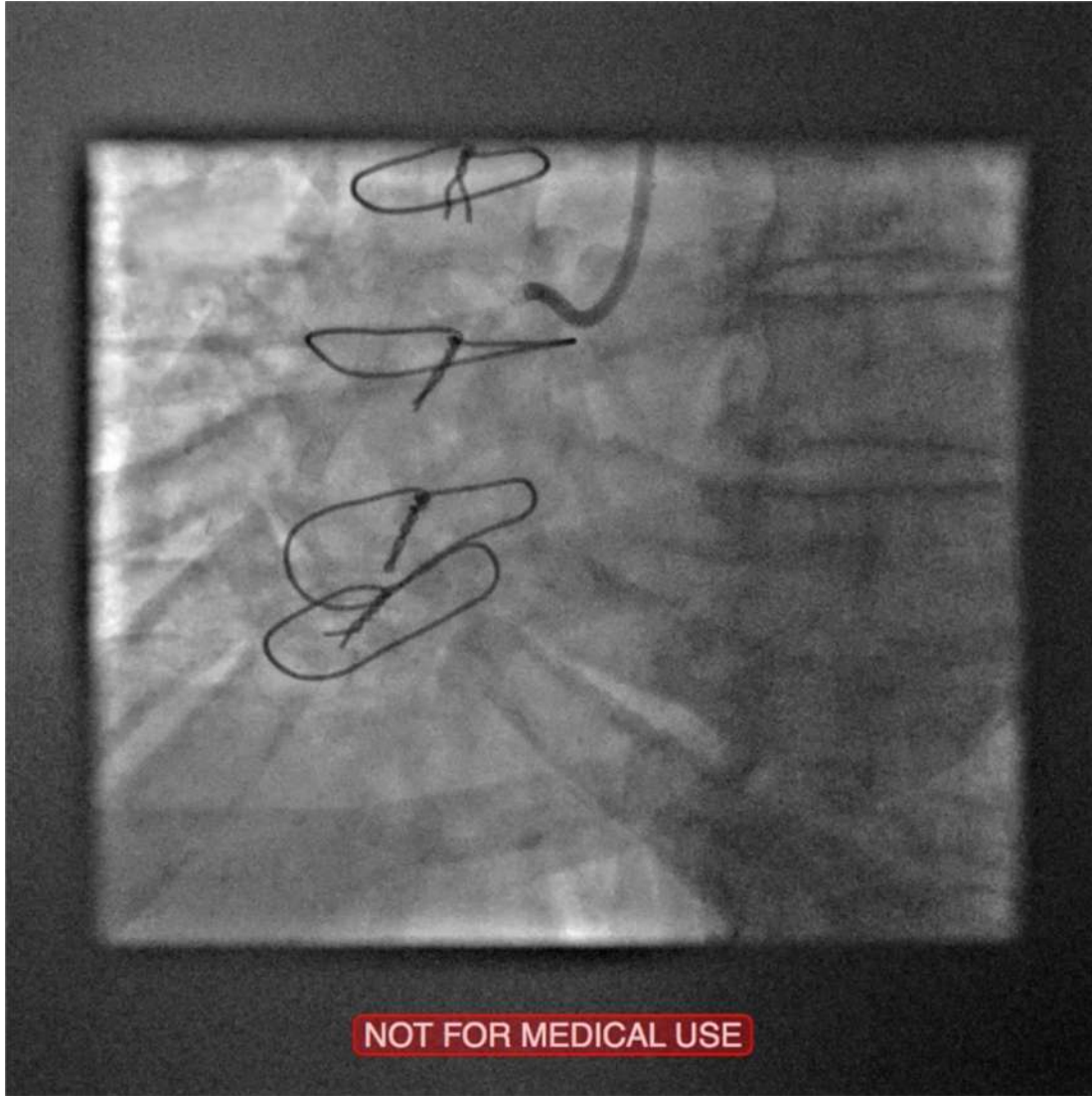- Patent LIMA-LAD & SVG-OM
- Occluded SVG-RPDA with severe RCA disease as culprit



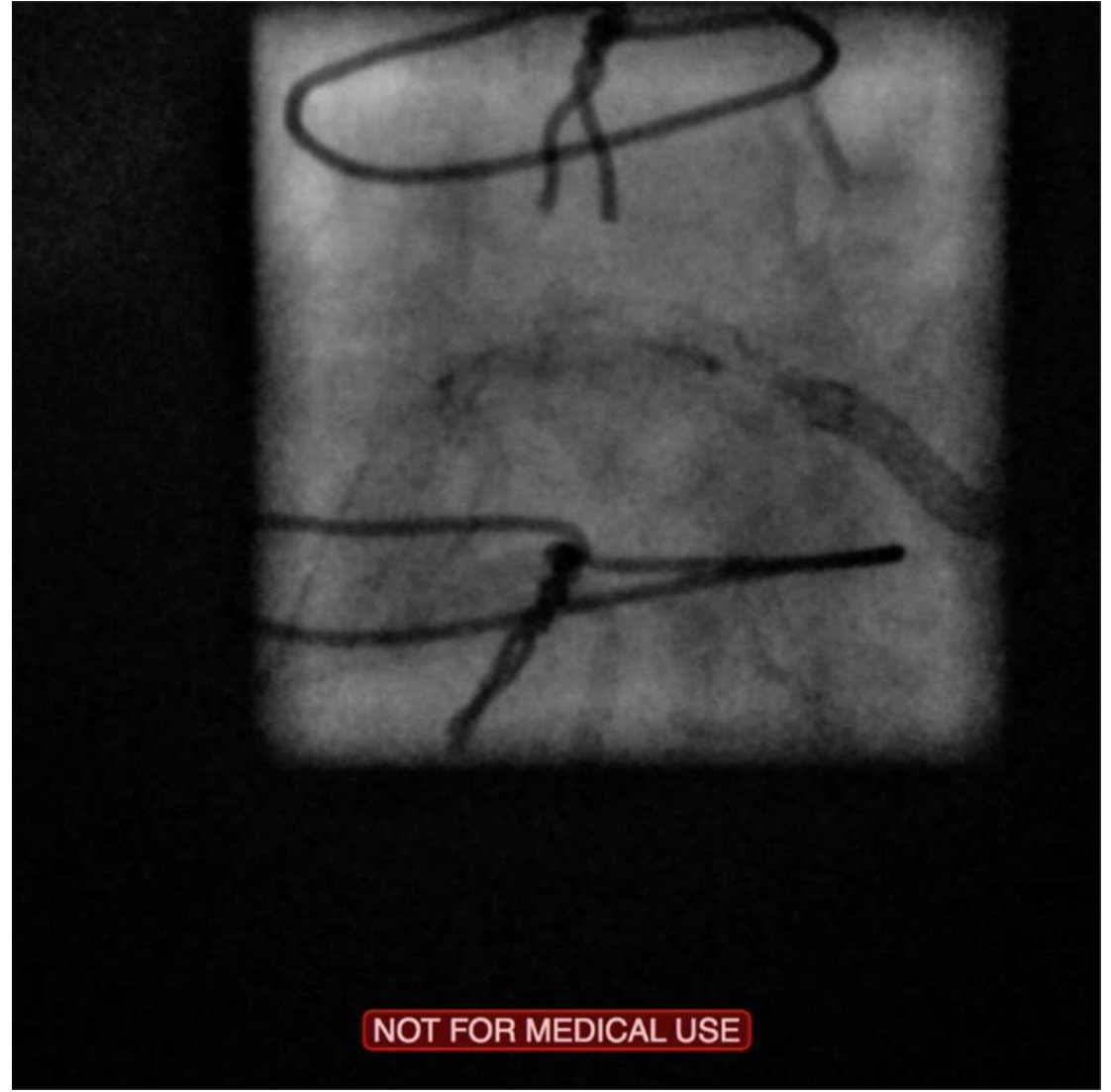# PCI to RCA

- Pre-dilated 3NC > Promus 3/38 & 3.5/38 > Under-expansion > 3.5NC > Scoreflex 3.5NC > OPN 40ats
- Ostial RCA dissection > Promus 3.5/8

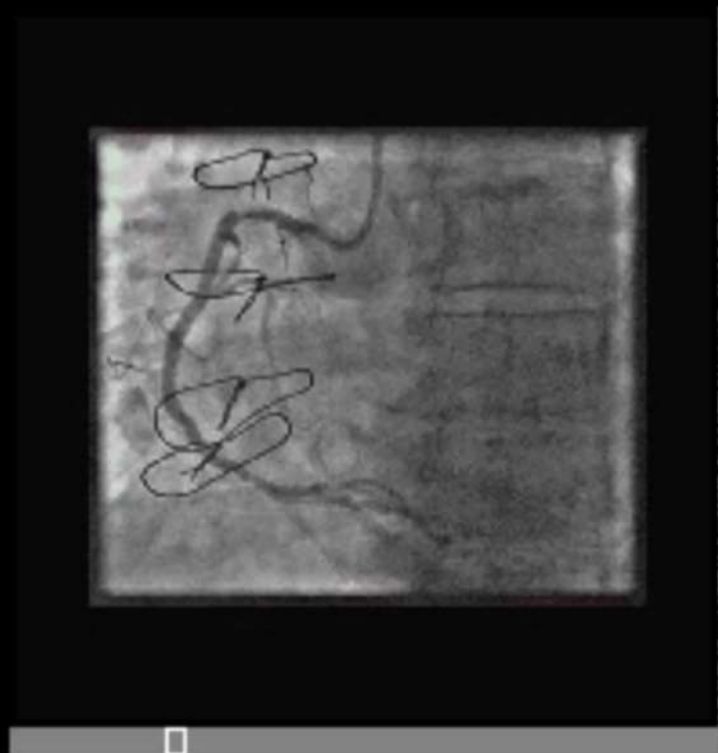# Staged Intravascular lithoplasty to under-expanded stent pRCA



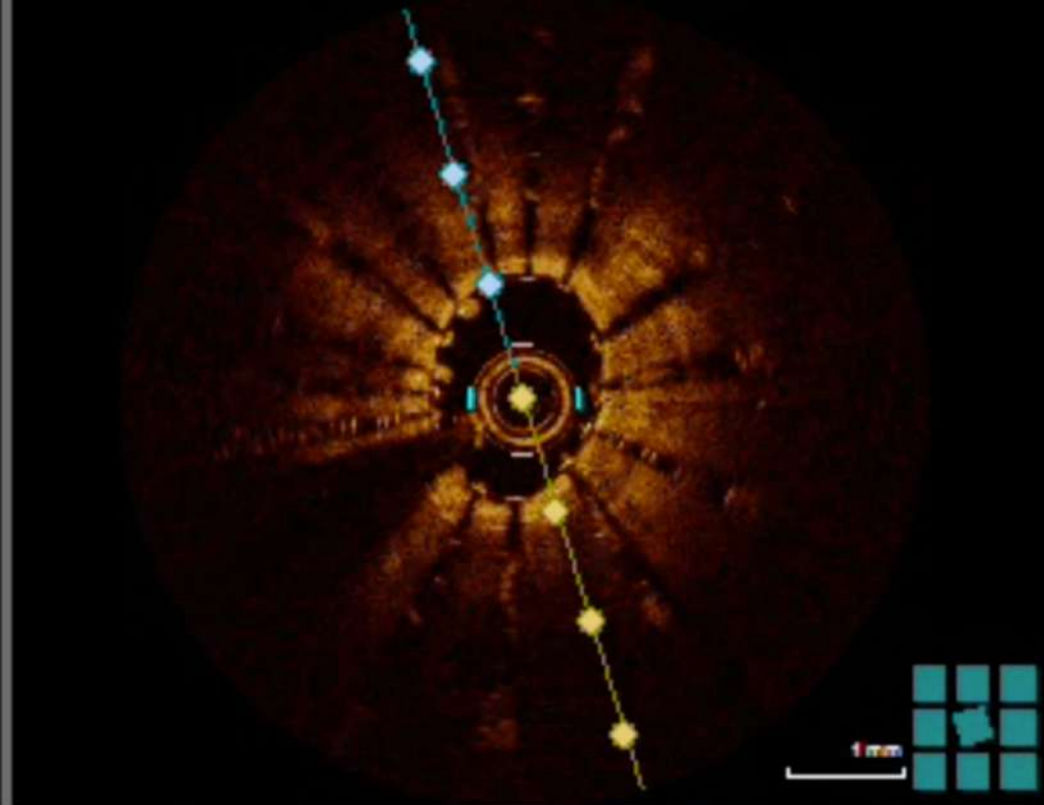
7F RRA & 7F AL0.75



'Stent vessel viz'  
Under-expansion & gap clearly seen



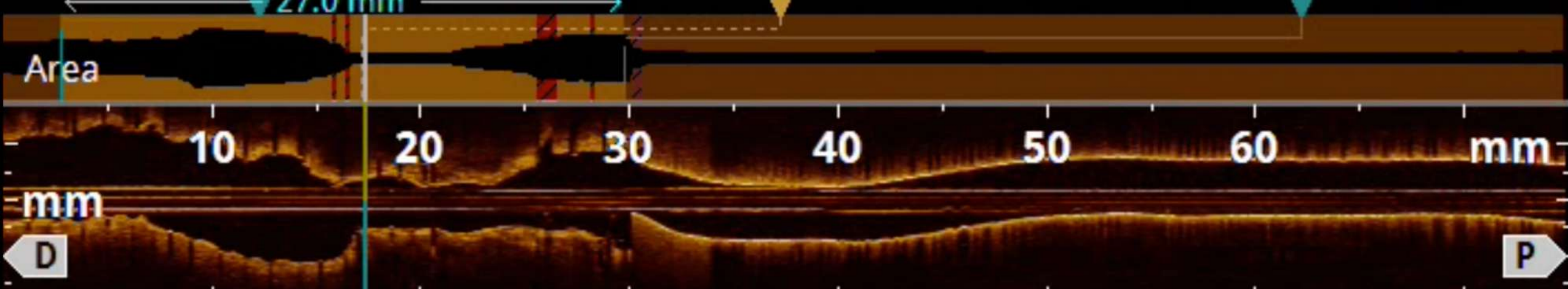
Pre-OCT  
under-  
expansion

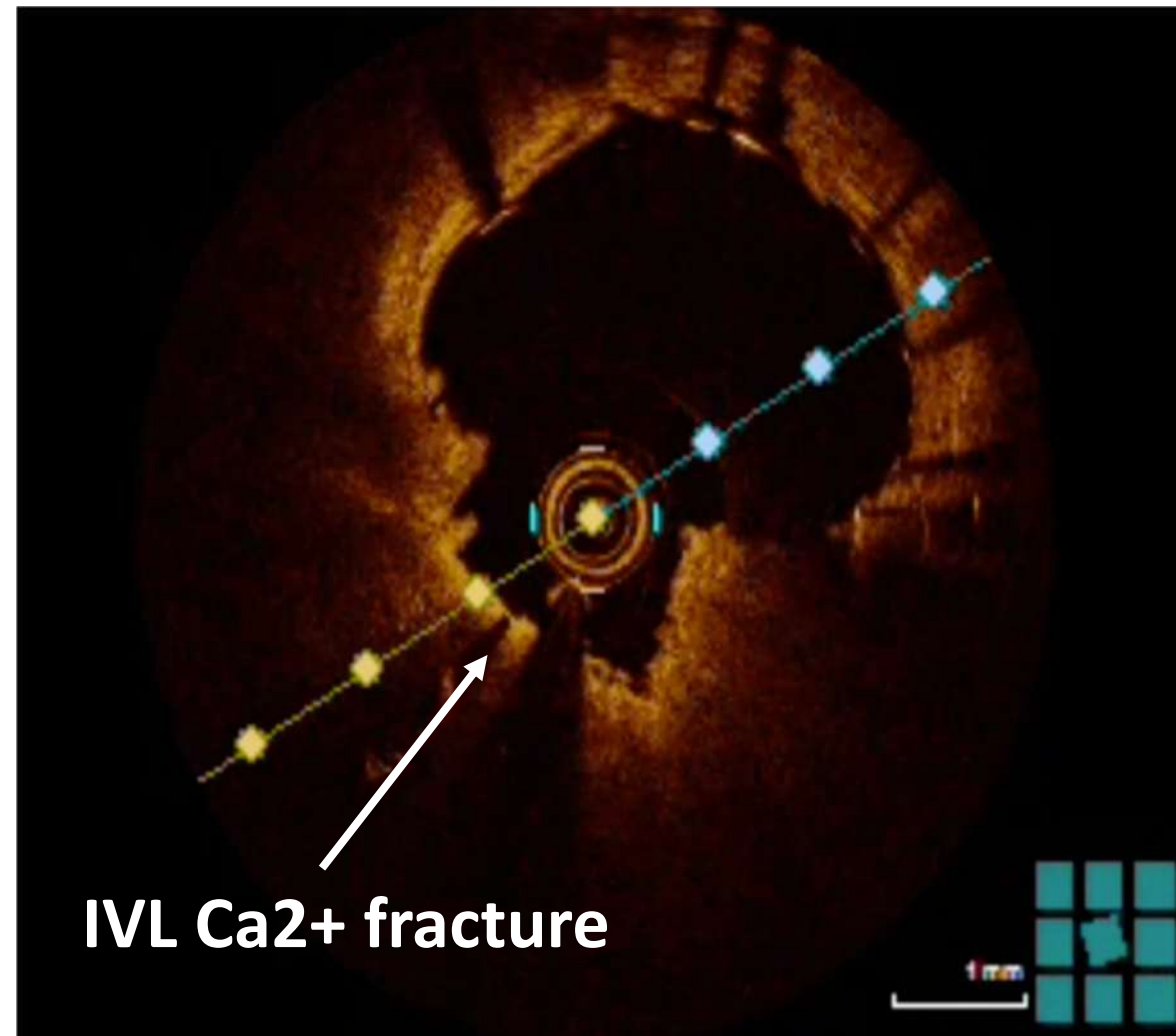
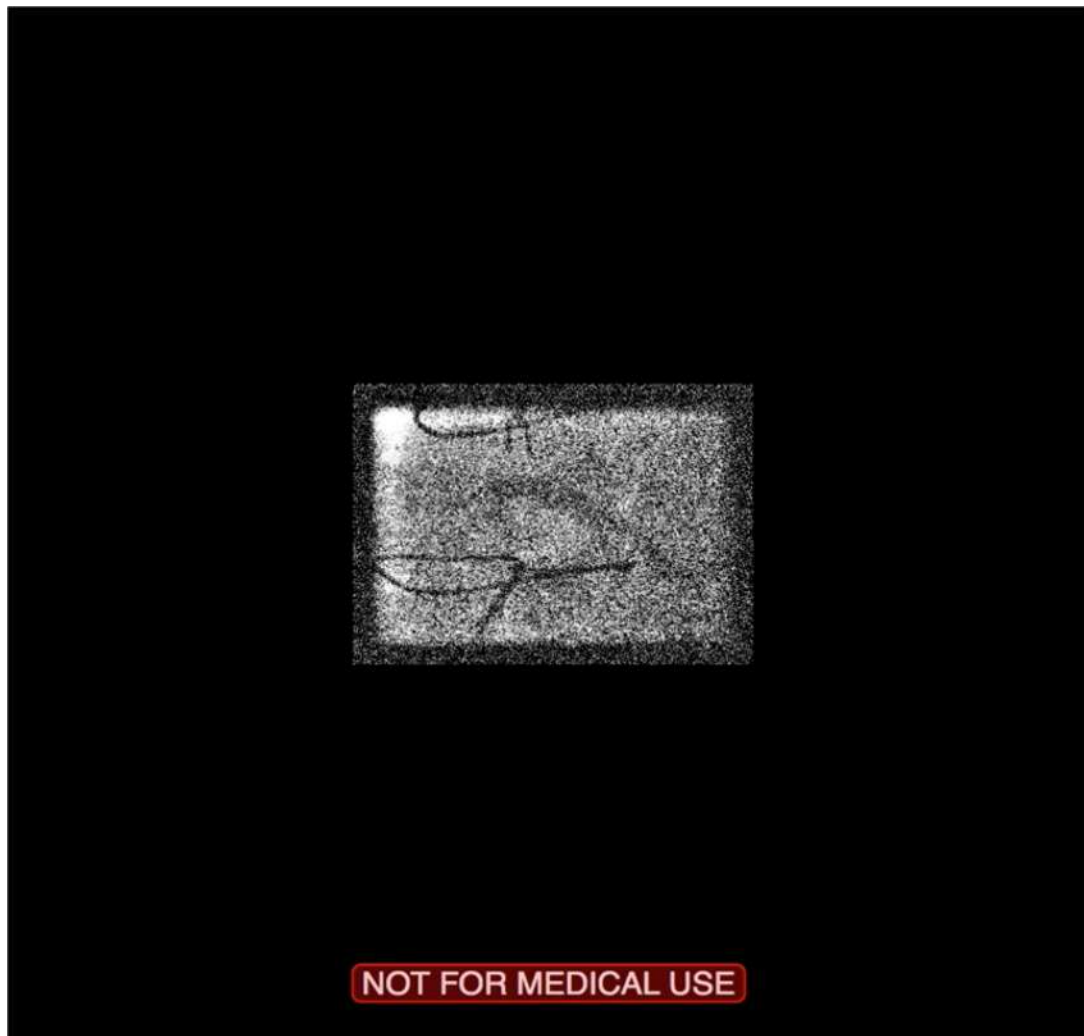


Area 8.21mm<sup>2</sup>  
Ø=3.22mm, DS=??.% , AS=??.%  
27.0 mm

MLA ?..mm<sup>2</sup>  
Ø=?..mm, DS=??.% , AS=??.%

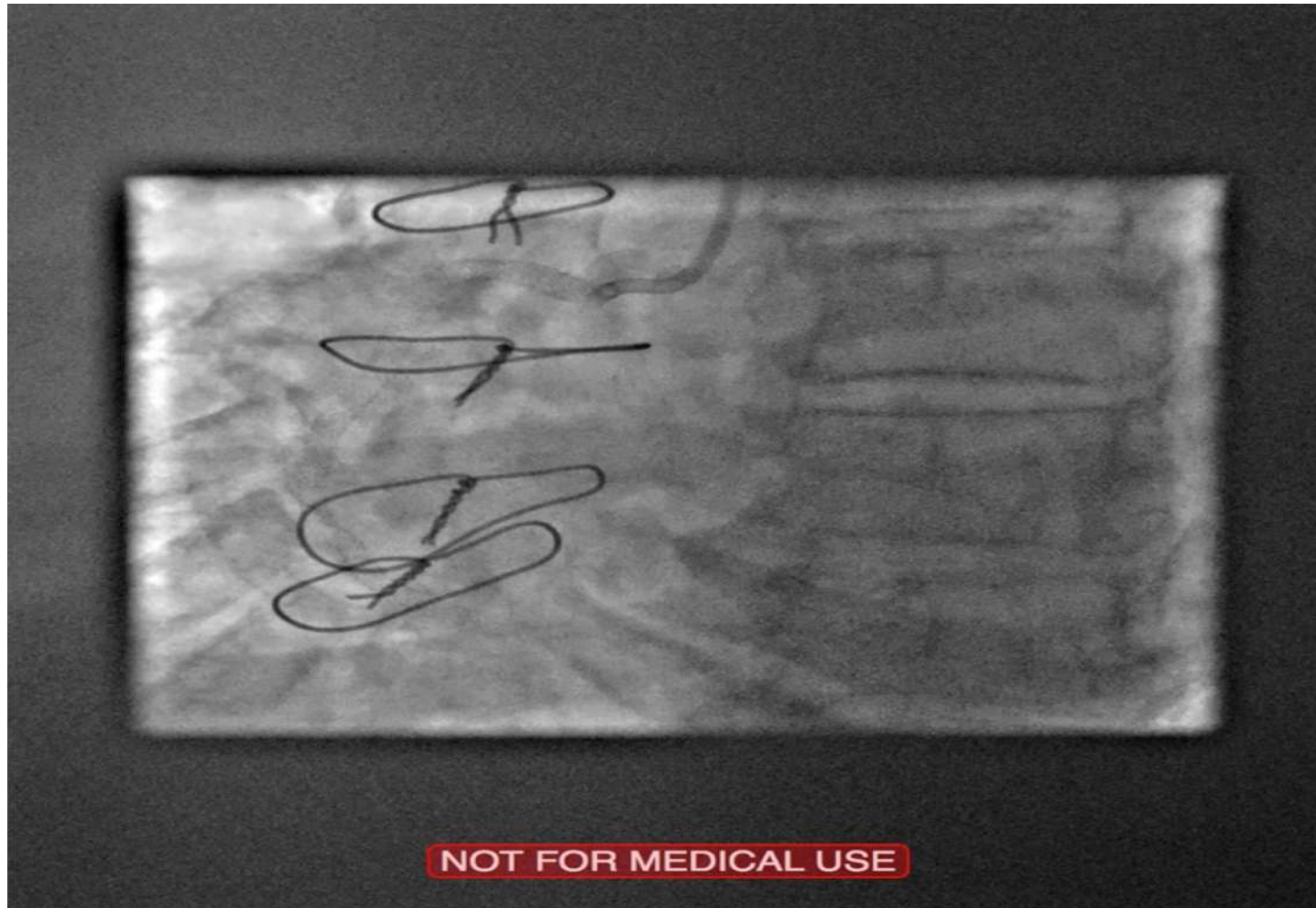
Area 10.78mm<sup>2</sup>  
Ø=3.70mm, DS=??.% , AS=??.%





'Shockwave' IntraVascular Lithotripsy (IVL)  
3.5mm balloon > 80 pulses

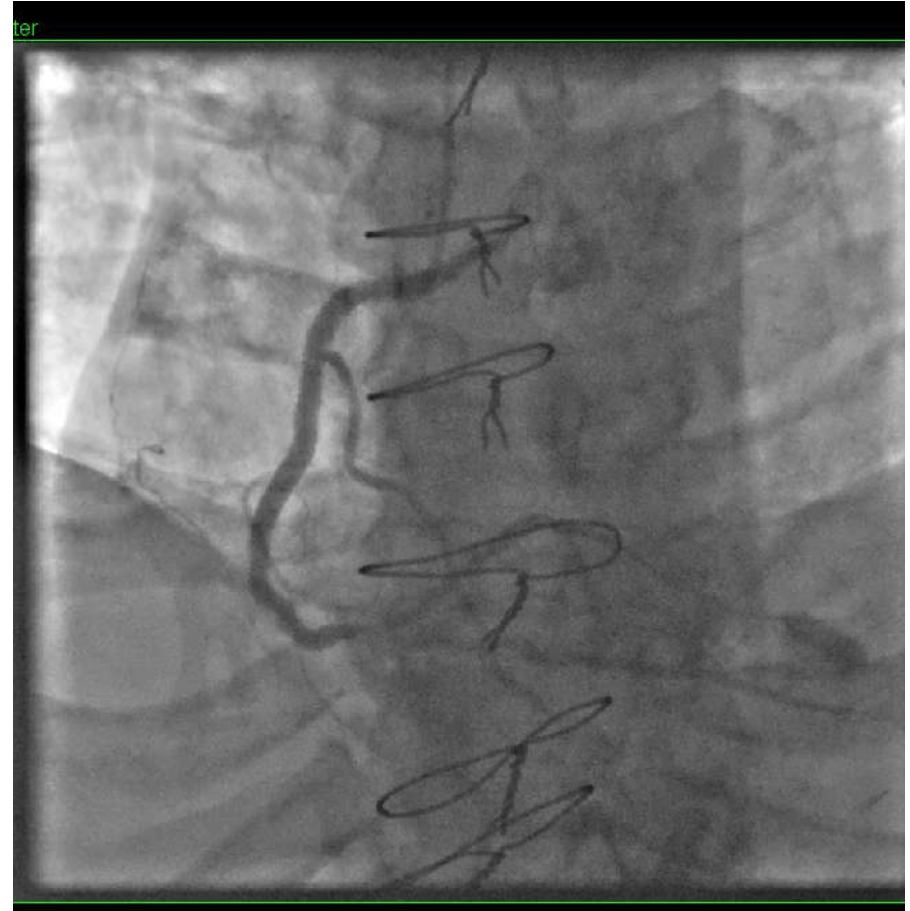# Final result



Promus 4/16 to bridge gap & 4NC

# Follow Up

- Unusual Presentation and indication for repeat angiography.



Thank you